

1

Dermatology
UNIVERSITY OF COLORADO

No conflicts of interest

2

Objectives

1. Differentiate Urticaria from Common Urticarial Mimickers
2. Discuss a Diagnostic and Treatment Approach in Clinical Practice
3. Evaluate the Mechanisms and Efficacy of Traditional and Emerging Therapies



3

Cutaneous diseases with urticarial lesions

Common
- Urticarial dermatitis
- Contact dermatitis
- Arthropod bite reaction
- Autoimmune bullous disease
- Pruritic urticarial papules & plaques of pregnancy (PUPPP)

Rare
- Autoimmune progesterone dermatitis
- Eosinophilic cellulitis (Wells syndrome)
- Urticaria-like follicular mucinosis

4

Systemic diseases with urticarial lesions

Vasculitides

(small vessel = urticarial lesions)
- UV, GPA, eGPA, cPAN

Rheumatologic disorder**
- SLE, Sjogren's, DM, MCTZ

Hematologic disease**
- Waldenstrom macroglobulinemia, Schnitzler syndrome, MGUS, Hypereosinophilic syndrome

Serum Sickness/SSLR**

Auto inflammatory syndromes**
- Hereditary periodic fever syndromes, Cryopyrin-assoc. periodic syndromes
- VEXAS
- Adult-onset Still's disease…

***Neutrophilic urticarial dermatoses*

5

Characteristics of Typical & Atypical Wheals

Common urticaria

Typical wheals
- Erythematous, edematous plaques
- Transient (<36 hours)
- Asymmetric distribution
- No residual skin changes
- Lack of secondary skin changes
- +/- Angioedema
- Dermatographism
- Pruritic

Urticarial Lesions

Atypical "wheals"
- Infiltrated plaques, +/- nonblanching
- Persistent (>36 hours)
- Symmetric distribution
- Residual skin changes
- Secondary skin changes
- Usually, no associated angioedema or dermatographism
- +/- Pruritic +/- burning, painful

6

Ordinary Urticaria



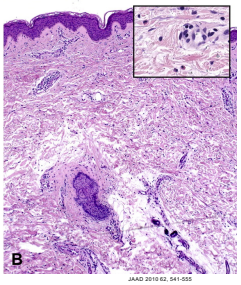

JAAD 2010 62, 541-555

7

Typical Wheals



Erythematous (blanching redness), edematous plaques

Atypical Wheals



Indurated/infiltrated plaques, Can be non-blanching

8

Typical Wheals

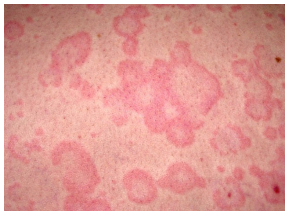

Different stages

Atypical Wheals



Similar stage

9

Typical Wheals



No associated changes

Atypical Wheals



Associated/secondary changes

10

Typical Wheals



No associated secondary changes

Atypical Wheals



Secondary changes

11

Typical Wheals



Atypical Wheals



Post-inflammatory Changes
Scarring

12

Typical Wheals



Atypical Wheals



14

Case 1

65-year-old male

- **Duration:** 9-month history
- **Symptoms:** Diffuse pruritic eruption
- **Systemic Symptoms:** None
- **Household Contacts:** No one else at home is itching
- **Medications/Exposures:** No recent medication changes or new contacts
- **Lesion Duration:** Uncertain how long each lesion lasts
- **Treatments:** TCS and antihistamines help

Pmhx: HTN, HLD

Meds: atorvastatin, diltiazem, aspirin

All: NKDA

SH: non-smoker, married



15

Case 1: Exam



16

Case 1

What is included in the differential diagnosis?

a. Chronic urticaria
b. Bullous pemphigoid
c. Urticarial dermatitis
d. Contact dermatitis
e. All of the above



17

Case 1

What is included in the differential diagnosis?

a. Chronic urticaria
b. Bullous pemphigoid
c. Urticarial dermatitis
d. Contact dermatitis
e. All of the above



18

Characteristics of Typical & Atypical Wheals

Typical wheals

- Erythematous, edematous plaques
- Transient (<36 hours)
- Asymmetric distribution
- Resolution without signs
- Lack of vesicles, crusts, purpura
- +/- Angioedema; Dermatographism
- Pruritic

Atypical "wheals"

- Infiltrated plaques, nonblanching
- Persistent (>36 hours)
- Symmetric distribution
- Resolves with signs
- Assoc. vesicles, scaling, crust
- Not associated with angioedema or dermatographism
- +/- Pruritic +/- burning, painful

19

Case 1

What is included in the differential diagnosis?

a. ~~Chronic urticaria~~
   - Atypical wheals

a. Bullous pemphigoid
   - H+E/ DIF

b. Urticarial dermatitis
   - Review medication list

d. Contact Dermatitis
   - Review exposures

e. All of the above



20

Urticarial Dermatitis



- Elderly patients (>60 y/o)
- Long standing, symmetric thin plaques with an urticarial appearance (+/- eczematous)
- Etiology unclear, most likely medication induced
  - BP meds (CCB) and diuretics
- Histology dermal edema with perivascular lymphocytic inflammation w/ eos +/- spongiosis
- Unrelieved with antihistamines; temporary relief with topical steroids
  - Oral steroids used for treatment

21

Urticarial Dermatitis

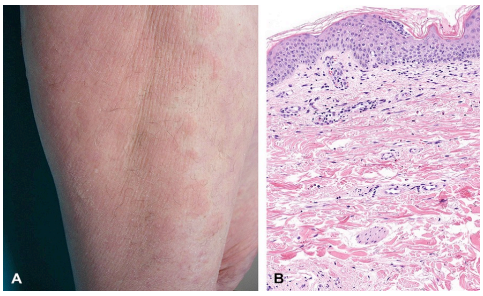

22

Urticarial Dermatitis



23

Case 2

Chief Complaint: A 42-year-old male
- 3-week history of daily fevers, joint pain
- Recurrent, non-pruritic urticarial rash

History of Present Illness:
- Evening fevers peaking at 39.5°C (103.1°F), associated with chills and night sweats.
- Symmetric polyarthritis involving wrists, knees, and ankles, with morning stiffness lasting over an hour.
- Pink, edematous plaques appearing daily on the trunk and proximal extremities, resolving within 24 hours without residual hyperpigmentation.
- Denies recent infections, new medications, travel history, or exposure to sick contacts.

- **ROS:**
  - NO lymphadenopathy, weight loss, or gastrointestinal symptoms
- **Past Medical History:**
  - No significant past medical history.
- **Medications:**
  - None.
- **Family History:**
  - No family history of autoimmune or rheumatologic diseases.

24

Case 2: Exam

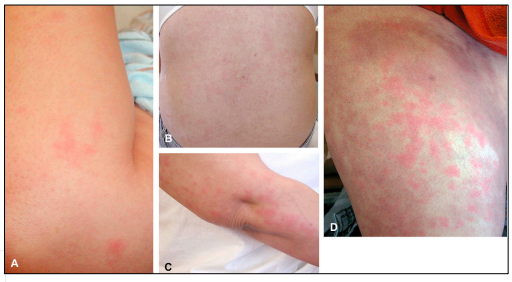

25

Case 2: Exam



26

Case 2 Exam

Laboratory Findings:

WBC 15,000/µL, neutrophil predominance), mild anemia, thrombocytosis.

ESR 78 mm/hr, CRP 12.5 mg/dL.

Mild elevation in AST/ALT.

Ferritin: 5,800 ng/mL

ANA, RF, CCP: Negative.

Blood Cultures: Negative.



27

Characteristics of Typical & Atypical Wheals

Typical wheals

- Erythematous, edematous plaques
- Transient (<36 hours)
- Asymmetric distribution
- Resolution without signs
- Lack of vesicles, crusts, purpura
- +/- Angioedema; Dermatographism
- Pruritic

Atypical "wheals"

- Infiltrated plaques, nonblanching
- Persistent (>36 hours)
- Symmetric distribution
- Resolves with signs
- Assoc. vesicles, scaling, crust
- Not associated with angioedema or dermatographism
- Not pruritic +/- burning, painful

28

Case 2 Skin Biopsy

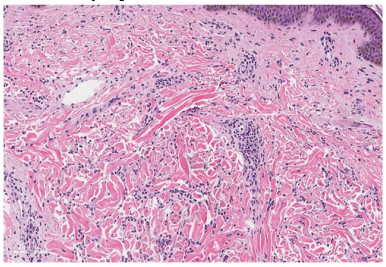

Superficial and deep dermal neutrophilic infiltrate without leukocytoclastic vasculitis

29

Systemic diseases with urticarial lesions

Vasculitides

(small vessel = urticarial lesions)

- UV, GPA, eGPA, cPAN

Rheumatologic disorder**

- SLE, Sjogren's, DM, MCTZ

Hematologic disease**

- Waldenstrom macroglobulinemia, Schnitzler syndrome, MGUS, Hypereosinophilic syndrome

Serum Sickness/SSLR**

Auto inflammatory syndromes**

- Hereditary periodic fever syndromes, Cryopyrin-assoc. periodic syndromes
- VEXAS
- Adult-onset Still's disease…

***Neutrophilic urticarial dermatoses*

30

Case 2

Which of the following is the most likely diagnosis?

a. Chronic urticaria
b. Bullous pemphigoid
c. Neutrophilic urticarial dermatitis
d. Contact dermatitis
e. Arthropod bite reaction



31

Case 2

Which of the following is the most likely diagnosis?

a. Chronic urticaria
b. Bullous pemphigoid
c. **Neutrophilic urticarial dermatitis**
d. Contact dermatitis
e. Arthropod bite reaction



32

Systemic diseases with Neutrophilic urticarial dermatoses

Rheumatologic disorder

- SLE, Sjogr

Hematologic d

- Waldenstr
  Schnitzler syndrome, HUSOS,
  Hypereosinophilic syndrome

Serum Sickness Like Reaction

Rheumatologic
Hematologic
Autoinflammatory

mes

- yer syndromes,
- dic syndromes

- Adult-onset Still's disease…

33

Case 2

Diagnosis:
Adult-Onset Still's Disease (AOSD)

Yamaguchi criteria:

- Daily fevers >39°C
- Arthritis
- Evanescent, urticarial-like rash
- Leukocytosis with neutrophilia
- Markedly elevated ferritin



34

Neutrophilic Urticarial Dermatosis (NUD)

Clinical Features of

- Pink urticarial eruption
- Pruritic or nonpruritic
- Resolves within 24 hours
- Fever or arthralgia

Histologic Features of NUD

- Intense neutrophilic interstitial and perivascular infiltrate
- No blood vessel damage or significant edema
- Neutrophilic epitheliotropism



35

Neutrophilic Urticarial Dermatosis (NUD)

1. Hematologic
2. Rheumatologic
3. Autoinflammatory

Box 5
Recommended laboratory tests if neutrophilic urticarial dermatosis is diagnosed[2]

Complete blood count (CBC)
CRP
ESR
Immunofixation serum protein electrophoresis
Ferritin ± glycosylated ferritin
Antinuclear antibodies, anti-dsDNA antibodies, anti-Ro/SSA antibodies, anti- La/SSB antibodies
UBA1 gene (VEXAS)

Dermatol Clin 42 (2024) 219–229

36

Urticarial Vasculitis

- Small vessel vasculitis
- Urticarial lesions persist 24-36 hours
- Burning > itching
- Resolve with hyperpigmentation or bruising
- +/- Purpura
- Angioedema in 50% of cases



38

Case 3

79 y/o healthy active

- 1 year of diffusely pruritic eruption on trunk and proximal extremities.
- Lesions last a "couple of days" and some longer.
- Treated for urticaria for the last year, but ATC antihistamines and topical steroids only provide some relief.
- Systemic steroids used to help, but less effective recently.

Negative ROS

PMhx: none

Meds: aspirin

All: NKDA

SHx: no tobacco, married, cyclist and runner



39

Case 3: Exam

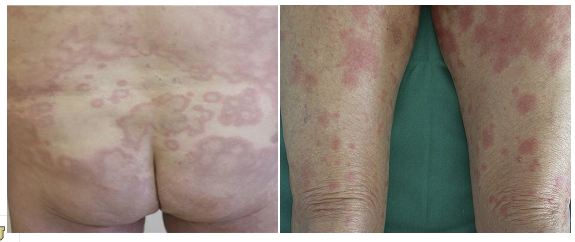

40

Case 3

What is included in the differential diagnosis?

a. Chronic urticaria
b. Bullous pemphigoid
c. Urticarial dermatitis
d. Contact dermatitis
e. Hematologic malignancy
f. All of the above



41

Case 3

What is included in the differential diagnosis?

a. Chronic urticaria
b. Bullous pemphigoid
c. Urticarial dermatitis
d. Contact dermatitis
e. Hematologic malignancy
f. All of the above



42

Case 3

What is included in the differential diagnosis?

a. Chronic urticaria
b. Bullous pemphigoid
   - H+E/perilesional DIF
c. Urticarial dermatitis
   - Medication history
d. Contact dermatitis
   - Exposure history
e. Hematologic malignancy
   - CBC w/ diff, SPEP/UPEP



43

Bullous Pemphigoid

- Autoimmune bullous disease in elderly
- Tense blisters that arise on urticarial plaques
  - Hemorrhagic bullae common
- Severe pruritus



44





Urticarial Stage Bullous Pemphigoid

- Not transient > 36 hours
- Associated scale, crusting, vesicles
- Post inflammatory pigmentation
- Symmetric
- No dermatographism or angioedema

45

Urticarial Stage (Prodromal) Bullous Pemphigoid



- Pruritus at an older age → clue
- Always perform DIF
- ELISA immunoserology (BPAg 180/230)
- DIF microscopy and IIF on SSS have a high specificity and sensitivity (98% and 100%, respectively)

46

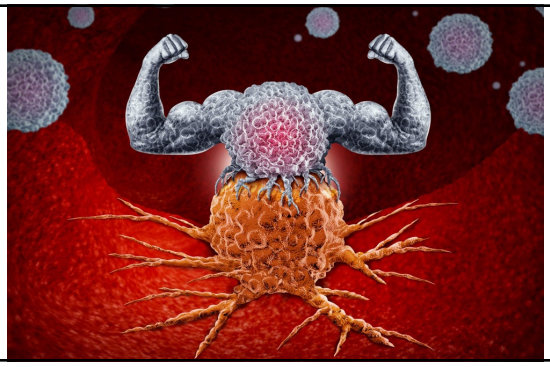

47

Indications for Biopsy in Urticaria

- Atypical lesions
- Systemic symptoms
- Concern for urticarial mimickers

Preferred Biopsy Technique:

- 2 punch biopsies (4mm) are ideal:
  - H&E
  - Direct immunofluorescence (DIF)
    - If suspect autoimmune blistering disease or vasculitis

Blood work based on biopsy results



48

Take Home Points

- **Identify Atypical Features**
- **Biopsy When in Doubt**
- **Urticaria with systemic symptoms**
  - Four key associated categories:
    - Vasculitides
    - Rheumatologic
    - Hematologic
    - Autoinflammatory

49



50

The international EAACI/GA²LEN/EuroGuiDerm/APAAACI guideline for the definition, classification, diagnosis, and management of urticaria



Allergy, Volume: 77, Issue: 3, Pages: 734-766, First published: 18 September 2021, DOI: (10.1111/all.15089)

51

Cyclosporine

- Best for rapid control of severe skin diseases
- Bridging therapy
- Ideal for short term use



53

Cyclosporine

Dosing & Administration

- **Typical dose**: 2.5–5 mg/kg/day (div BID)
  - Urticaria dosing: 1-3 mg/kg/day (div BID)
- Dose adjustments based on **renal function, blood pressure, and side effects**

Pharmacokinetics

- Metabolized in the **liver (CYP3A4 enzyme)**
- Drug levels influenced by **food, grapefruit juice, and drug interactions**

Adverse Effects

- **Nephrotoxicity** (dose-dependent)
- **Hypertension** (common)
- **Hyperlipidemia** (increases LDL, triglycerides)
- **Gingival hyperplasia**
- **Hypertrichosis**
- **Neurotoxicity** (tremor, headache, paresthesias)
- **Increased infection risk**
- **Increased risk of malignancy** (especially **non-melanoma skin cancers** and **lymphomas**)

54

Cyclosporine

Mechanism of Action

- **Calcineurin inhibitor** → suppresses **T-cell activation** by inhibiting IL-2 production

- **Contraindicated**
  - Uncontrolled hypertension
  - Renal dysfunction
  - Malignancy

Monitoring Parameters

- **Baseline labs**:
  - CBC, CMP, Mag
  - Blood pressure
  - *Lipids, uric acid*

- **Follow-up**:
  - CBC/CMP, Mag
    - q 2weeks x 4 weeks
    - Monthly x 4 months, then q3 months
  - *Lipids, uric acid*
  - Home blood pressure checks

55

Maoz-Segal et al. World Allergy Organization Journal (2020) 13:100448
http://doi.org/10.1016/j.waojou.2020.100448

WORLD ALLERGY ORGANIZATION JOURNAL
Open Access

Combination therapy with omalizumab and an immune-suppressive agent for resistant chronic spontaneous urticaria - A real-life experience

Ramit Maoz-Segal[a,b], Tanya Levy[a], Soad Haj-Yahia[a,b], Irena Offengenden[a], Mona Iancovich-Kidon[a,b] and Nancy Agmon-Levin[a,b]

The Journal of Allergy and Clinical Immunology: In Practice
Volume 6, Issue 2, March–April 2018, Pages 586-599

Original Article

Cyclosporine for Chronic Spontaneous Urticaria: A Meta-Analysis and Systematic Review

The Journal of Allergy and Clinical Immunology: In Practice
Volume 8, Issue 6, June 2020, Pages 2101-2103

Clinical Communications

Cyclosporine and omalizumab together: A new option for chronic refractory urticaria

Low dose cyclosporine 1-3mg/kg/day

56

Emerging Therapies



58

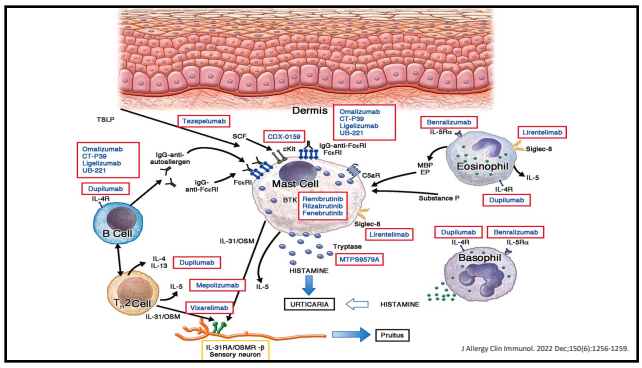

J Allergy Clin Immunol. 2022 Dec;150(6):1256-1259.

59

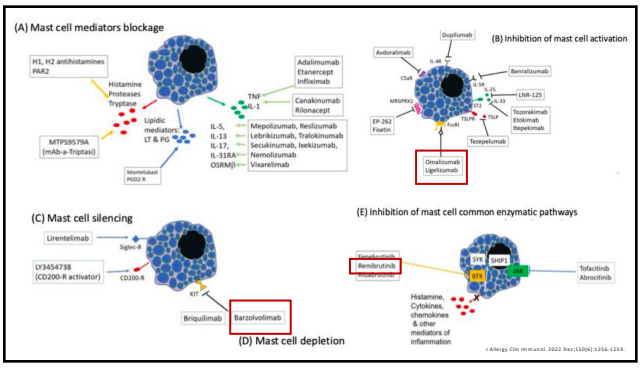

J Allergy Clin Immunol. 2022 Dec;150(6):1256-1259.

60

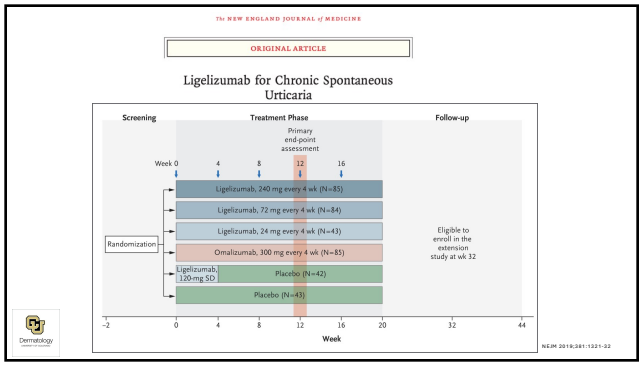

61

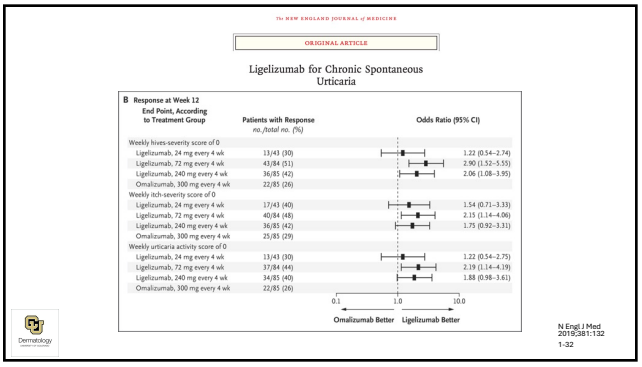

62

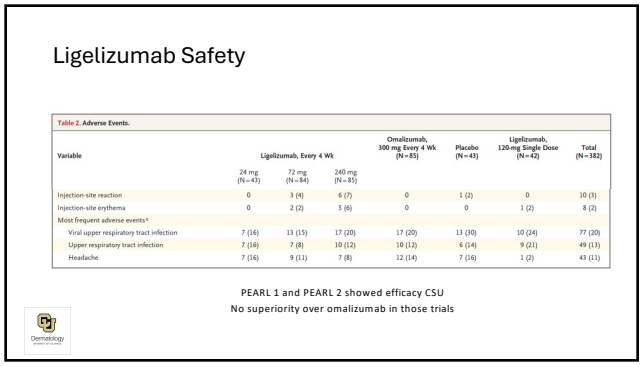

63

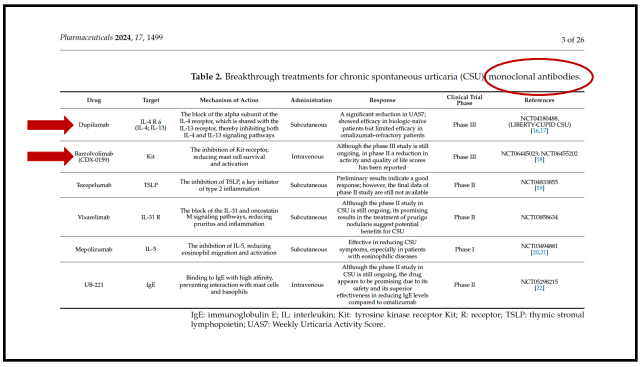

64



65

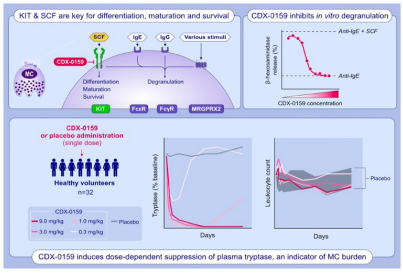

66

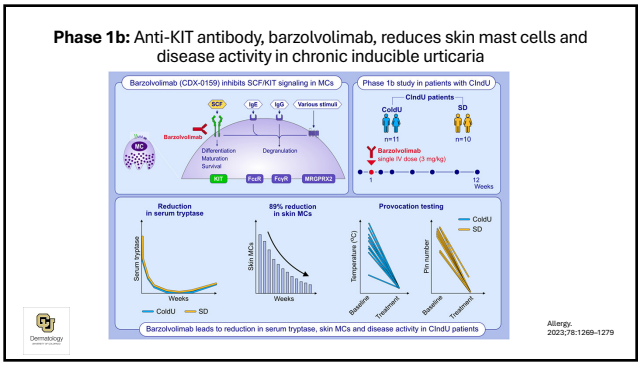

67

Celldex Therapeutics Presents Landmark 52 Week Results from Barzolvolimab Phase 2 Study in Chronic Spontaneous Urticaria at EADV 2024

September 25, 2024 | 10 min read

Preliminary safety signal: mild hematologic, infusion reactions, hair color alterations, taste disturbances, headaches, and potential increased risk of infections

68

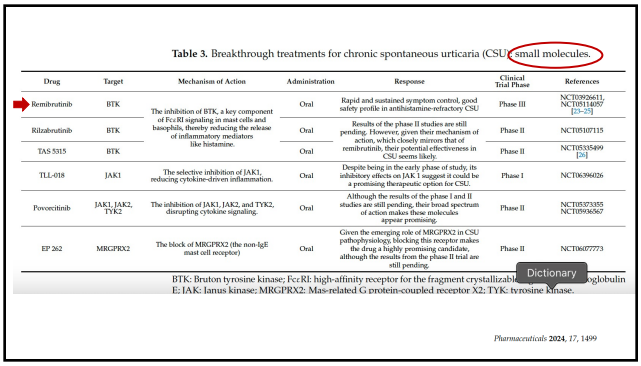

Table 3. Breakthrough treatments for chronic spontaneous urticaria (CSU): small molecules.

Drug	Target	Mechanism of Action	Administration	Response	Clinical Trial Phase	References
Remibrutinib	BTK	The inhibition of BTK, a key component of FcεRI signaling in mast cells and basophils, thereby reducing the release of inflammatory mediators like histamine.	Oral	Rapid and sustained symptom control, good safety profile in antihistamine-refractory CSU	Phase III	NCT03926611, NCT05114057 [23–25]
Rilzabrutinib	BTK		Oral	Results of the phase II studies are still pending. However, given their mechanism of action, which closely mirrors that of remibrutinib, their potential effectiveness in CSU seems likely.	Phase II	NCT05107115
TAS 5315	BTK		Oral		Phase II	NCT05335499 [26]
TLL-018	JAK1	The selective inhibition of JAK1, reducing cytokine-driven inflammation.	Oral	Despite being in the early phase of study, its inhibitory effects on JAK 1 suggest it could be a promising therapeutic option for CSU.	Phase I	NCT06396026
Povorcitinib	JAK1, JAK2, TYK2	The inhibition of JAK1, JAK2, and TYK2, disrupting cytokine signaling.	Oral	Although the results of the phase I and II studies are still pending, their broad spectrum of action makes these molecules appear promising.	Phase II	NCT05373355 NCT05936567
EP 262	MRGPRX2	The block of MRGPRX2 (the non-IgE mast cell receptor)	Oral	Given the emerging role of MRGPRX2 in CSU pathophysiology, blocking this receptor makes the drug a highly promising candidate, although the results from the phase II trial are still pending.	Phase II	NCT06077773

Dictionary

BTK: Bruton tyrosine kinase; FcεRI: high-affinity receptor for the fragment crystallizable region of immunoglobulin E; JAK: Janus kinase; MRGPRX2: Mas-related G protein-coupled receptor X2; TYK: tyrosine kinase.

Pharmaceuticals **2024**, *17*, 1499

69

70

Remibrutinib demonstrates favorable safety profile and sustained efficacy in chronic spontaneous urticaria over 52 weeks

Vipul Jain, MBBS, FRCPC,[a] Ana Giménez-Arnau, MD,[b] Koremasa Hayama, MD, PhD,[c] Adam Reich, MD, PhD,[d] Warner Carr, MD, FACP,[e] Jeffrey Tillinghast, MD,[f] Swapnil Dahale, MSc,[g] Karine Lheritier, PhD,[f] Pauline Walsh, PhD,[f] Artem Zharkov, MD,[h] Sophie Hugot, MSc,[h] and Sibylle Haemmerle, PhD[h]
Hamilton, Ontario, Canada; Barcelona, Spain; Tokyo, Japan; Rzeszów, Poland; Mission Viejo, Calif; St Louis, Mo; Mumbai, India; Basel, Switzerland; and Dublin, Ireland

FIG 3. Change from baseline in UAS7 during treatment period (as observed; safety set). n, number of patients with assessment at the specified time point.

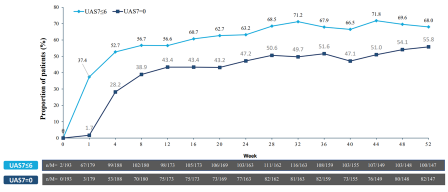

J Allergy Clin Immunol 2024;153:479-86

71

Remibrutinib Safety

TABLE III. Most frequent TEAEs by primary system organ class and preferred term—treatment period (safety set) (N = 194)

	Remibrutinib 100 mg b.i.d., no. (%)
TEAEs by primary system organ class*	
Infections and infestations	60 (30.9)
Skin and subcutaneous tissue disorders	52 (26.8)
Gastrointestinal disorders	32 (16.5)
Musculoskeletal and connective tissue disorders	26 (13.4)
Nervous system disorders	23 (11.9)
Injury, poisoning, and procedural complications	21 (10.8)
General disorders and administration site conditions	20 (10.3)
TEAEs by preferred term†	
Chronic spontaneous urticaria	22 (11.3)
COVID-19	16 (8.2)
Headache	13 (6.7)
Eczema	10 (5.2)

Adverse events occurring during treatment or within 28 days of the last study medication are summarized. MedDRA Version 25.0 (www.meddra.org) was used for reporting of adverse events. *AE*, Adverse event; *COVID-19*, coronavirus disease; *N*, total number of patients; *no.*, number of patients in each category.
*Occurring in ≥10% of patients.
†Occurring in ≥5% of patients.

J Allergy Clin Immunol 2024;153:479-86

72

Dual Biologics



73

Dual Biologics

DERMATOLOGIC THERAPY
LETTER

Combined treatment with omalizumab and secukinumab in a patient with chronic spontaneous urticaria and psoriasis

Özge Sevil Karsarlı Bakay, Nida Kacar

First published: 15 June 2022 | https://doi.org/10.1111/ddh.15638 | Citations: 1

Australasian Journal of Dermatology
ORIGINAL RESEARCH

Omalizumab treatment in combination with any other biologics: Is it really a safe duo?

Sema Koç Yıldırım MD, Ece Erbağcı MD, Aslı Hapa MD

First published: 03 March 2023 | https://doi.org/10.1111/ajd.14019

FULL TEXT ARTICLE

Anti–IL-23 treatment with tildrakizumab can be effective in omalizumab-refractory chronic spontaneous urticaria: A case series

Hanna Bonnekoh MD, Lea Kiefer MD, Thomas Buttgereit MD, Pavel Kolkhir MD, Marie Lütke-Eversloh MSc, Jörg Scheffel PhD, Marcus Maurer MD and Martin Metz MD

Journal of Allergy and Clinical Immunology: In Practice, 2023-08-01, Volume 11, Issue 8, Pages 2578-2580.e1, Copyright © 2023 American Academy of Allergy, Asthma & Immunology

74

ActaDV
448
SHORT COMMUNICATION

Combining Omalizumab with Another Biotherapy

Anne-Claire FOUGEROUSSE[1], Pierre-André BECHEREL[1], Valérie PALLURE[2], Thierry BOYÉ[3], Ziad REGUIAI[4], Germaine GABISON[5], Hughes BARTHELEMY[6], Antoine BADAOUI[7], Emmanuel MAHÉ[8] and Cristina BULAI LIVIDEANU[9]; for the GEM ResoPso
[1]Departments of Dermatology: [2]Military Teaching Hospital Bégin, 69 avenue de Paris, FR-94160 Saint-Mandé, [3]Private Hospital of Antony, Antony, [4]Hospital Center of Perpignan, Perpignan, [5]Military Teaching Hospital Sainte-Anne, Toulon, [6]Courtanay Polyclinic, Reims, [7]Hospital Center of Auxerre, Auxerre and [8]Victor Dupouy Hospital Center, Argenteuil, [9]Dermatology practice, Saint-Maurice, and [4]Paul Sabatier University, CReference Center of Mastocytosis (CEREMAST); Department of Dermatology, Toulouse Teaching Hospital, Toulouse, France.
E-mail: ac.fougerousse@gmail.com

Accepted Feb 5, 2019 ; E-published Feb 6, 2019

Patient	Age, years/ Sex	Biotherapy indication	Biotherapy type	Biotherapy duration, months	CSU duration, months	Omalizumab treatment duration, months
#1	28/F	Psoriasis	Secukinumab	6	12	3
#2	35/F	Psoriasis	Adalimumab	9	24	8
#3	25/F	Psoriasis	Adalimumab	64	84	9
#4	21/F	Crohn's disease	Infliximab	18	12	4
#5	29/M	Ankylosing spondylarthritis	Etanercept	48	60	9
#6	60/F	Psoriasis	Infliximab	72	24	3
#7	25/M	Ulcerative colitis	Adalimumab	10	10	7
#8	51/M	Psoriasis	Etanercept	36	144	10
#9	49/M	Psoriasis and psoriasis arthritis	Etanercept	37	NA	12
#10	53/F	Psoriasis	Etanercept	108	2	12
	Mean 37.6	Gastrointestinal: 2 Dermatology: 7 Rheumatology: 1	ETN: 4 IFX: 2 ADA: 3 SECU: 1	40.8	41.3	7

CSU: chronic spontaneous urticaria; ETN: etanercept; IFX: infliximab; ADA: adalimumab; SECU: secukinumab; NA: not available.

Acta Derm Venereol 2019; 99: 448–449

75

Take Home Points

- **Anti-IgE Biologics Remain the Foundation**
- **Emerging Targets Beyond IgE**
  - IL-4/IL-13 (dupilumab), IL-5 (mepolizumab), (IL-17) secukinumab, (IL- 31) nemolizumab …
- **Bruton's Tyrosine Kinase (BTK)** and **KIT Inhibitors** offer new pathways
- **Dual Biologic Therapy is an Emerging Strategy**
- **Personalized Treatment Strategies** are on the horizon

76

Collaboration



77



78